

A FOUR-LEGGED AFRICAN PENGUIN *SPHENISCUS DEMERSUS* CHICK

ALBERT SNYMAN^{1*}, DAVID G. ROBERTS¹ & KATRIN LUDYNIA^{1,2}

¹*Southern African Foundation for the Conservation of Coastal Birds (SANCCOB), Table View 7441, Cape Town, South Africa*
 *(albert@sanccob.co.za)

²*Department of Biological Sciences, University of Cape Town, Rondebosch 7701, South Africa*

Received 05 October 2021, accepted 10 November 2021

ABSTRACT

SNYMAN, A., ROBERTS, D.G. & LUDYNIA. 2022. A four-legged penguin *Spheniscus demersus* chick. *Marine Ornithology* 50: 5–6.

Here we report an African Penguin *Spheniscus demersus* chick that was removed from Stony Point, South Africa with two supplementary feet; one supplementary foot was located near the cloaca between the left foot and the tail, and the other supplementary foot was situated just behind the left foot.

Key words: African penguin, polymelia

INTRODUCTION

Polymelia (additional limbs) and polydactyly (additional digits) appear to be rare in seabirds (see Woehler *et al.* 2020, and below). Indeed, only three cases of supplementary limbs have been reported in penguins (Voisin *et al.* 2002, TPP 2013, Vanstreels *et al.* 2018), despite this seabird species being very well investigated throughout the world, both historically and at the present time. A King Penguin *Aptenodytes patagonicus* chick having a third foot was recorded at Possession Island, Crozet Archipelago (46°25'48.14"S, 51°44'11.58"E) in 1966 (Voisin *et al.* 2002), and a Magellanic Penguin *Spheniscus magellanicus* chick with two additional flippers was recorded at Punta Tombo, Argentina (44°2'46.32"S, 65°13'26.20"W) (TPP 2013). The third case was of an adult African Penguin *S. demersus* having a supplementary foot and was admitted to the Southern African Foundation for the Conservation of Coastal Birds (SANCCOB) on 06 December 2010. This individual was euthanized after considering its poor prognosis and the intense pain induced by severe wounds on the bird's left tarsal joint, apparently caused by a watercraft propeller (Vanstreels *et al.* 2018).

OBSERVATIONS

Here, we report an African Penguin chick that was removed from Stony Point (34°22'27"S, 18°53'43"E) on 09 August 2019 and was admitted to SANCCOB. Upon admission, no other injuries were observed except for the two supplementary feet; one supplementary foot was located near the cloaca between the left foot and the tail, and the other supplementary foot was situated just behind the left foot (Fig. 1). The penguin was unable to move these two limbs and, after considering its poor prognosis, welfare issues, and suspected anticipated complications with foraging and diving post-fledging, the decision was made to euthanize the bird.

Post-mortem examination revealed that the supplementary feet were fully developed but had no mobility. Dissection of supplementary limbs revealed that both femur shafts were fused at the base of the ischium (Fig. 2). Both tibiotarsus, fibulas, and feet (with all digits) were fully developed (polydactyly) but had no function or mobility.

The femur length measured 64 mm and the tibiotarsus length measured 87 mm.

Besides the multiple supplementary limbs that provided justification for euthanasia, the penguin was found to be healthy and had no other significant pathological findings on necropsy. At 2.3 kg, the bird was in good physical condition, with well-developed chest

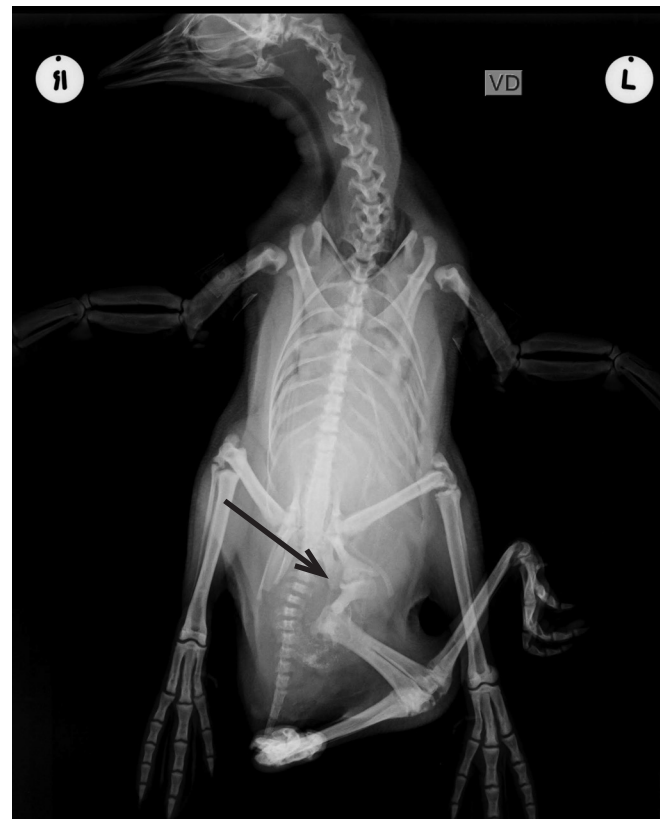

Fig. 1. Radiograph of supplementary limbs of an African Penguin *Spheniscus demersus* chick; arrow indicates where both femur shafts were fused at the base of the ischium.

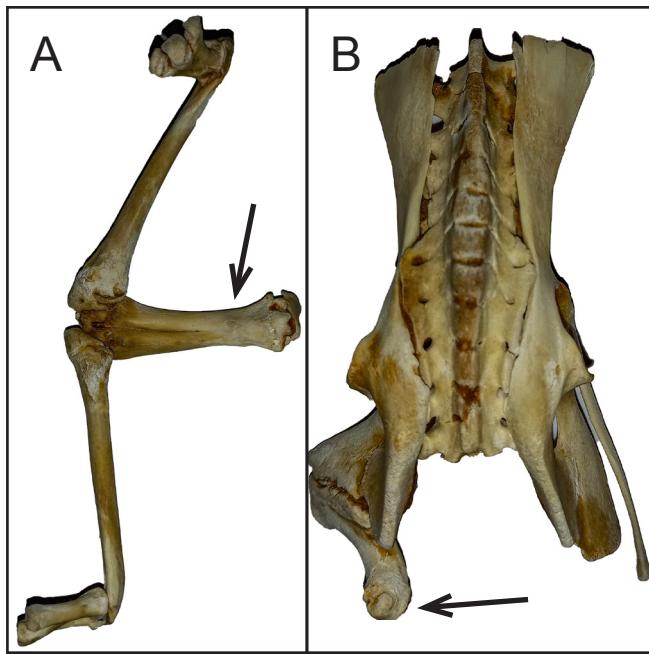


Fig. 2. Bone structure of supplementary limbs of an African Penguin *Spheniscus demersus* chick: (A) both femur shafts fused; (B) ischium fused where femur shafts were connected.

musculature, abundant subcutaneous fat, and a stomach containing digested prey items. Based on its mass and plumage, the chick appeared to be older than 45 d (Sherley *et al.* 2014).

DISCUSSION

Polymelia in penguins is a seldom-reported condition, likely because it is rare in wild populations, and indeed, this is likely only the second record in wild penguins. Other deformities found in penguins include the cases mentioned above, as well as micromelia reported in Little Penguins *Eudyptula minor* (Raidal *et al.* 2006). Polymelia and polydactyly have been reported in larids (Austin 1969, Ryder & Chamberlain 1972, Woehler & Holzmann 2020).

Possible causes for such deformities could be exposure to pollutants (Hays and Risebrough 1972, Buckle *et al.* 2014) and abnormalities in the development of limb buds (Vanstreels *et al.* 2018). The most likely explanation, however, are genetic errors during DNA replication (Ryder & Chamberlain 1972, Voisin *et al.* 2002). We suggest that the low incidence of polymelia in penguins arises simply because the causative factors occur very rarely. Ultimately, recording these abnormalities may prove to be valuable in the event

that such patterns might reflect issues such as pollution or genetic complications (Ryder & Chamberlain 1972, Gilbertson *et al.* 1976, Voisin *et al.* 2002, Buckle *et al.* 2014).

ACKNOWLEDGEMENTS

The authors thank the staff and volunteers working at the Southern African Foundation for the Conservation of Coastal Birds (SANCCOB) who performed rehabilitation work, as well as Ralph Vanstreels and an anonymous reviewer who provided helpful comments. SANCCOB is supported by a wide range of donors.

REFERENCES

- AUSTIN, O.L. 1969. Extra toes on a Sooty Tern chick. *The Auk* 86: 352.
- BUCKLE, K.N., YOUNG, M.J. & ALLEY, M.R. 2014. Investigation of an outbreak of craniofacial deformity in Yellow-eyed Penguin (*Megadyptes antipodes*) chicks. *New Zealand Veterinary Journal* 62: 250–257. doi:10.1080/00480169.2014.906332
- GILBERTSON, M., MORRIS, R.D. & HUNTER, R.A. 1976. Abnormal chicks and PCB residue levels in eggs of colonial birds on the lower Great Lakes (1971–73). *The Auk* 93: 434–442.
- HAYS, H. & RISEBROUGH, R. 1972. Pollutant concentrations in abnormal young terns from Long Island Sound. *The Auk* 89: 19–35.
- RAIDAL, S.R., SHEARER, P.L., CANNELL, B.L. & NORMAN, R.J.B. 2006. Micromelia in Little Penguins (*Eudyptula minor*). *Journal of Avian Medicine and Surgery* 20: 258–262.
- RYDER, J.P. & CHAMBERLAIN, D.J. 1972. Congenital foot abnormality in the Ring-billed Gull. *Wilson Bulletin* 84: 342–344.
- SHERLEY, R.B., WALLER, L.J., STRAUSS, V., GELDENHUYS, D., UNDERHILL, L.G., PARSONS, N.J. 2014. Hand-rearing, release and survival of African penguin chicks abandoned before independence by moulting parents. *PLoS One* 9: 1–8. doi:10.1371/journal.pone.0110794
- TPP (THE PENGUIN PROJECT). 2013. Spring/summer 2013 Penguin Project update. [Available online at: http://www.penguinstudies.org/wp-content/uploads/2014/09/2013_Spring_Update.pdf. Removed online by authors no longer available]
- VANSTREELS, R.E.T., PARSONS, N.J., & PISTORIUS, P.A. 2018. A three-legged African Penguin *Spheniscus demersus*. *Marine Ornithology* 46: 23–26.
- VOISIN, J.F., MOUGIN, J.L., SEGONZAC, M. & ROPERT COUDERT, Y. 2002. Colour aberrations and physical deformities in the King Penguin *Aptenodytes patagonicus* at the Crozet Islands. *Marine Ornithology* 30: 1–4.
- WOEHLER, E.J. & HOLZMANN K.L. 2020. Polymelia and polydactyly in a Silver Gull *Chroicocephalus novaehollandiae*. *Marine Ornithology* 48: 169–170.